

# Managing Bone Augmentation and Maintenance in Conjunction with Immediate Implant Placement for Gap Filling and Implant Stability

Prof. Dr. Jose' Luis Calvo Guirado, DDS, PhD, Eu PhD, MS

## Clinical Case Overview

### *Patient History and Chief Concern*

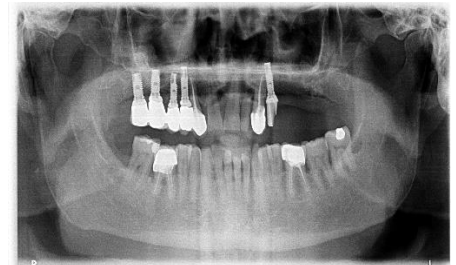A 65-year-old male patient presented for comprehensive evaluation and treatment. His medical history did not reveal any abnormal indications. Aside of poor dental hygiene, no contraindications for dental treatment was observed. The patient has already undergone implant placement all in the maxilla. The patient's chief concern was a pain in mandibular left and right central incisors as well as aesthetic concerns (Figure 1,2).

### *Diagnosis and prognosis*

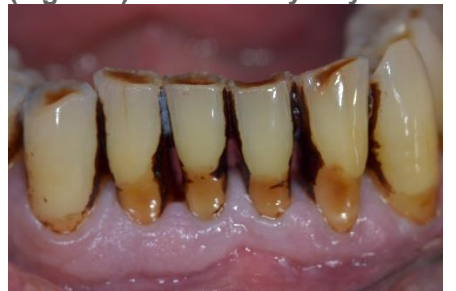Clinical and radiographic examination revealed High mobility and pain in teeth 32,31,41,42 (23,24,25,26) that were all periodontally involved. Bone resorption was observed in the mandibular central region as well. Our prognosis was that mobility would not reverse and in fact periodontal disease could continue to infect neighboring teeth. Also, progressive bone loss is expected.

## Bone Filling Therapies

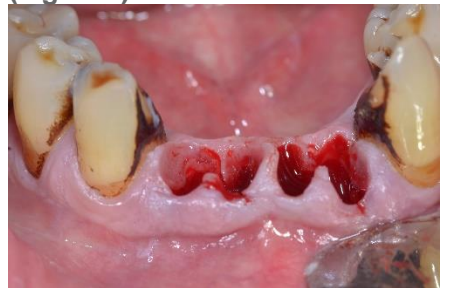Post teeth extraction, significant bone defects can be observed especially in situations where periodontally compromised situations exist. In such cases, it is recommended to fill the defect using grafting procedures in an attempt to return the alveolar bone to a manageable dimension as well as return full function. Typically done in conjunction with implant placement or prior to it. These therapies require assessment, site preparation, grafting and membrane placement. The hope is that the material will integrate with the site bone and convert into natural bone, meantime providing sufficient support and stability for implant integration.



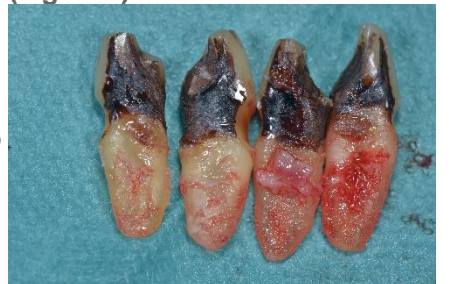(Figure 1) – Preliminary xray



(Figure 2) – Bone loss



(Figure 3) - Extraction



(Figure 4) – Extracted incisors

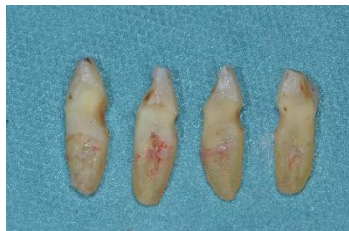## Treatment

The four lower incisors were extracted and converted into autologous dentin graft which was then used to fill the defect in the extraction site. Two implants were immediately placed, and provisional was provided. In the maxilla three implants placed in preparation for a bridge and gap filled with remaining dentin graft to add to implant stability and integration. Screw on bridge was provided after 4 months of healing.

## Procedure

A periodontal involved 1<sup>st</sup> and 2<sup>nd</sup> lower incisors left, and right were extracted. Once extracted, the teeth were cleaned using a high speed bur to remove any periodontal ligaments, soft tissue, cementum and debris. The four teeth were then dried using air-syringe. The teeth were then ground into appropriate particulate size using the KometaBio Smart Dentin Grinder and cleansed and washed using the KometaBio cleanser kit solutions. After this 15 minute process, the dentin graft was ready for use. During the dentin graft cleansing process, two Straumann Bone Level 3.3 narrow Implants were placed in position 42 and 32 teeth sockets. Two temporary implants were placed in 31 and 41 missing teeth sockets. All bone gaps and defects were filled with the dentin graft material. The site was then sutured for primary closure and a provisional fixture was placed. After a healing period of four months, a permanent four-unit bridge was screwed onto the narrow implants. At the at time of surgery, a gingival flap was performed at the maxillary site where three implants were then placed and gap was then grafted with the remaining dentin graft. A collagen resorbable membrane was then placed and site was sutured.

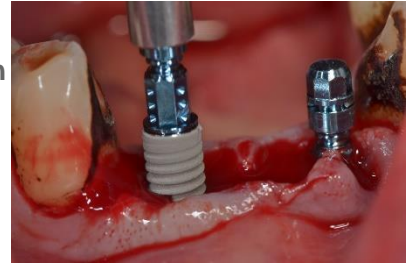
### KometaBio – Smart Dentin Grinder Protocol:



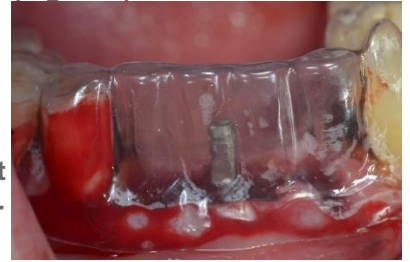(Figure 5) Teeth post cleaning  
(Figure 7 – below) – Graft output



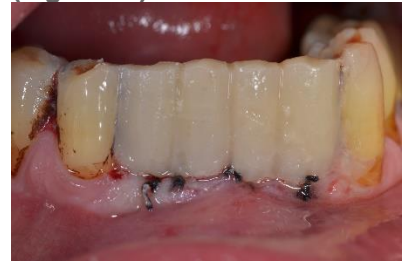(Figure 6) – SDG Chamber  
(Figure 8 – below)



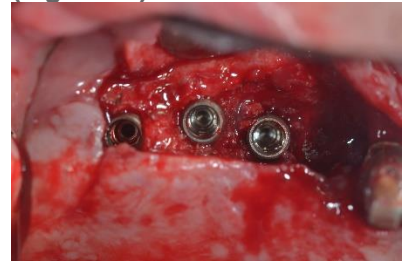
(Figure 9)



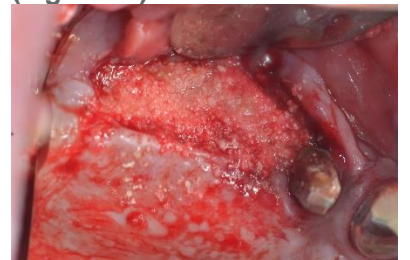(Figure 10)



(Figure 11)



(Figure 12)



(Figure 13)

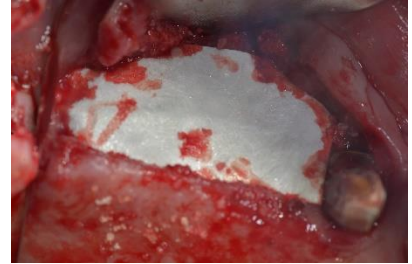After a healing period of four months, a three-unit bridge was affixed. It should be noted that the four extracted incisors were enough to graft both the mandible extraction site as well as the maxillary augmentation site.

## Results

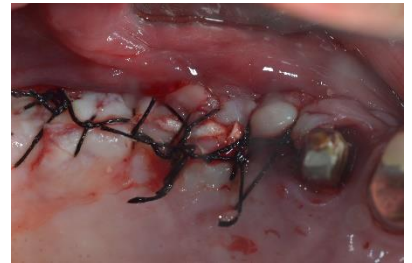An excellent aesthetic outcome was achieved in this case by managing the hard tissue and soft tissue healing in both sites, achieving strong implant integration and stability that nicely supports the prosthodontic work. The 4-month follow up presented very nice tissue healing, and sufficient bone density. Both sites presented good vascularization and bleeding. The 12-month follow up presented a continued bone build-up and no visible resorption.

## Conclusion

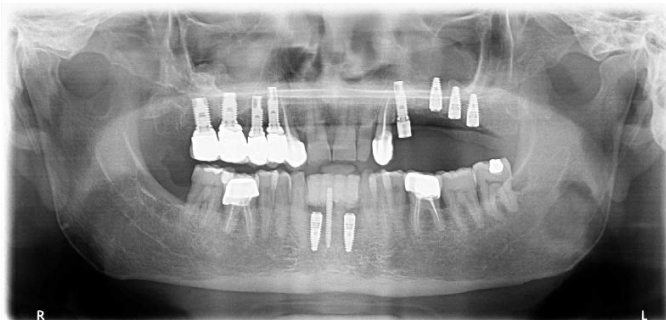
We find the dentin graft technique, using the KometaBio Smart Dentin Grinder protocol, to be highly predictive in achieving short term and long-term success in bone gap filling and ridge maintenance.



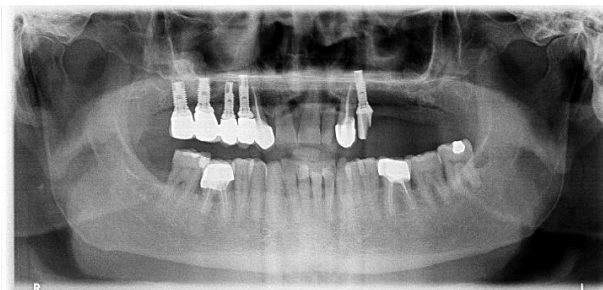
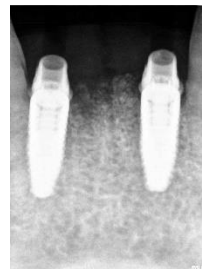(Figure 14) - Membrane



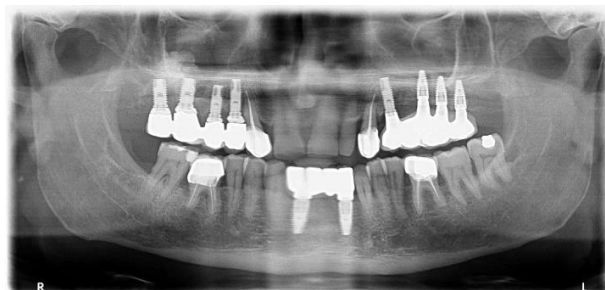(Figure 15) – suturing maxillary site



(Figure 16) – 4 month follow up



(Figure 17 – BEFORE)



(Figure 18 – AFTER) – 12 month follow up