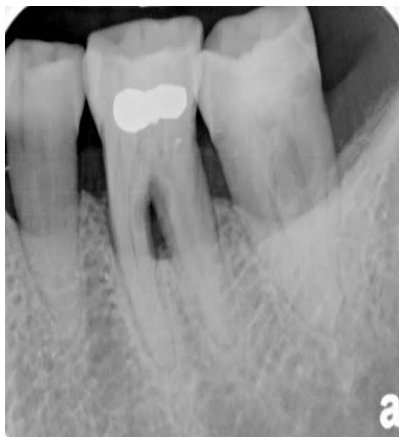

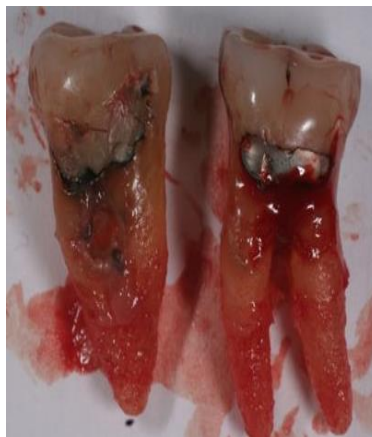Dentin grafting, implant placement and prosthetic restoration in 5 month

Case description: Tooth #36 and #37 were extracted because of periodontal involvement and bone loss. The sockets were grafted and during 5 month a permanent restoration on implants was accomplished.

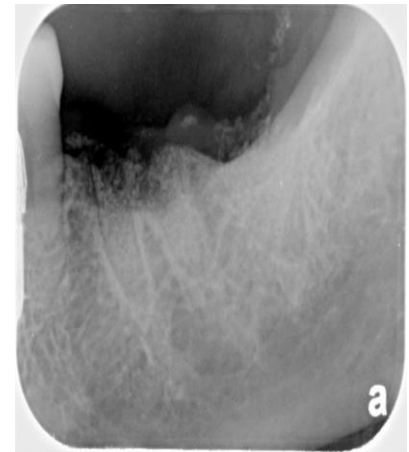
Result: Autologous dentin graft allows shorter healing period, augmentation of the ridge and high stability of implant.



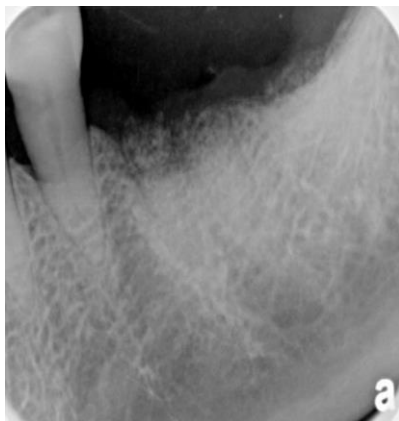December 2014



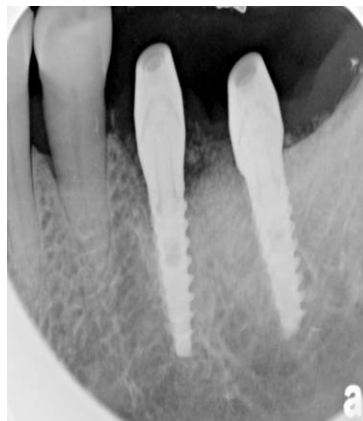Extraction – Dec. 2014



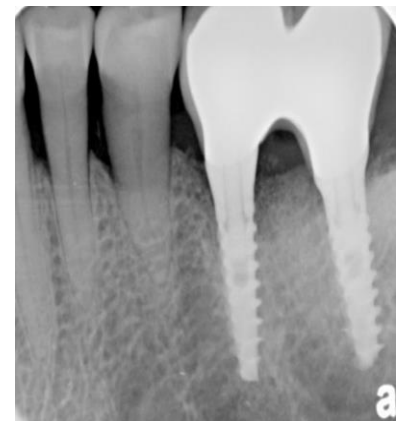Dentin Grafting – Dec. 2014



Grafted site – Feb. 2015



February 2015



April 2015

Dr. Gideon Hallel DMD MPA