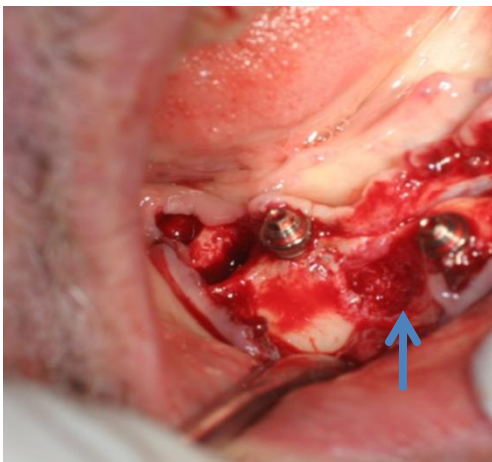


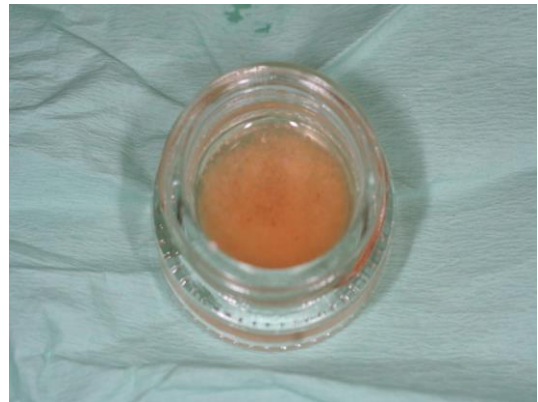Advanced perio case for grafting and implants – dentin graft and minerOSS comparison (part 1)

Case description: Full restoration of mandible with 7 implants where dentin graft was used on the right side and MinerOSS was used on the left side. Extraction sites grafted with Autologous Dentin, in the right side while MinerOSS on the left side of mandible. Implants were placed in between extractions site into the crest. A day later a cast temporary reconstruction was placed on implants. PRF membrane was used on both sides.

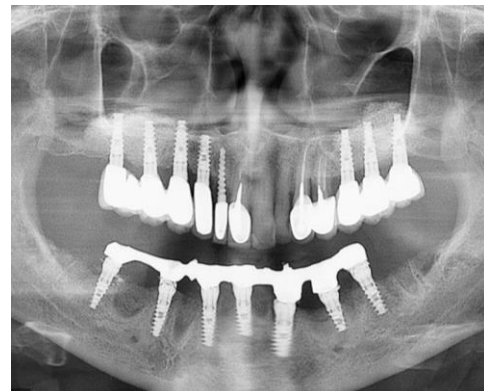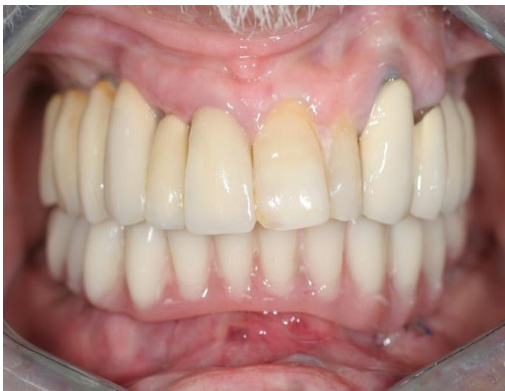Results: Predictable aesthetic results for full mandible restoration based on autologous dentin grafting. **Dentin graft leverages ankylosis which makes it possible to fast pace the restoration and achieve long term aesthetic effect.**



Dentin graft



PRF with dentin graft



24 hours post grafting and implant insertion a temporary prosthesis was prepared