

How to Transform Extracted Teeth into an Autologous Bone Graft in a Single Dental Appointment

In most cases the tooth socket is significantly remodelled after the extraction of a tooth. Filler material is required to be placed in the socket before a dental implant or prosthesis can be put in place in order to maintain the bone volume and thus preserve aesthetics and allowing normal restoration. Drs Dominique ESTRADE and Emmanuel METIVIER

The ideal bone filler material is osteoconductive, osteoinductive and osteogenic^{1,2}. This is why the autologous bone graft, with its known limits, is considered to be the reference graft. There is, however, another autologous biomaterial that has the same properties and same consistency as cortical bone that we have readily available at our dental surgeries when extracting teeth –

The same composition as bone

Dentin is formed from the same ingredients as bone, i.e.:

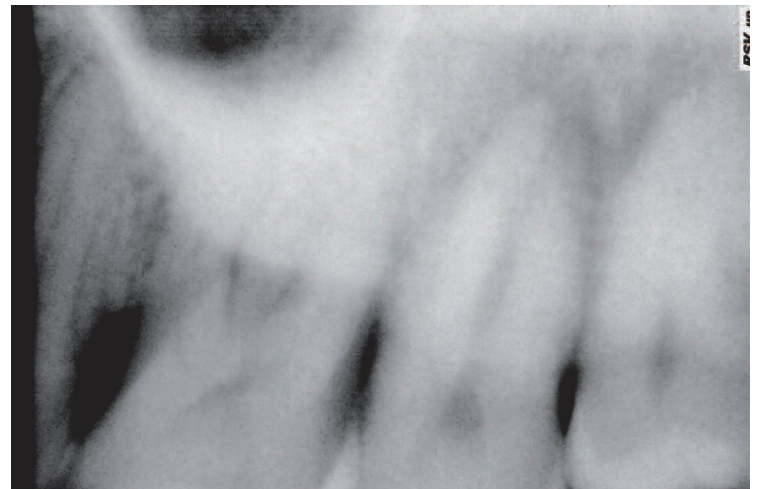- Type I collagen (more than 90% of its organic compounds) which plays a key role in the bone formation
- Bone Morphogenetic Proteins (BMP) which promote bone formation^{3,4}, and other non-collagenous proteins

Experimental studies on animals and subsequent clinical studies have highlighted

Dr Itzhak Binderman, a bone tissue specialist of the University of Tel-Aviv and Dr Lari Sapoznikov, have developed a system allowing an extracted tooth to be transformed into decontaminated dentin particulate, ready for autologous implantation into their newly liberated tooth sockets or bone defects, in an easy three-step procedure:



Smart Dentin Grinder: Tooth grinding and dentin particulate sorting system. The 250 to 1200 μ m particles are collected in the drawer and then decontaminated before being re-implanted in the tooth socket for an autologous graft.



Initial Case

The osteoconductive, osteoinductive and osteogenic properties of dentin and its ability to incite bone formation.^{5,6}

The concept, however, is not new since we have known for decades that a tooth that is extracted and re-implanted may undergo ankylosis. This ankylosis is caused by the osteogenic cells present in the tooth socket from which the tooth was extracted, which attach to the radicular surface of the tooth and then differentiate by turning into bone. The bone formation cycle causes slow root resorption until the root has completely disappeared and is replaced by bone after five to ten years.

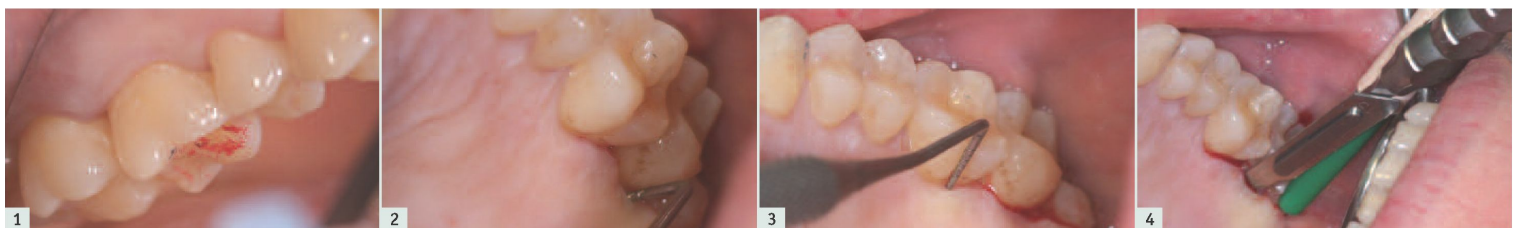A first solution, allowing dentin to be used as a bone graft material was developed in South Korea and Japan over 10 years ago. However, the complexity of the protocol limits it to hospital use or alternatively requires the services of a specialised company.


1. Extraction of the Tooth, elimination of food substances and removal of organic debris. The enamel does not have to be removed since it is made of hydroxylapatite. NB. Teeth that have undergone an endodontic treatment cannot be used in this procedure.

2. Grinding (3 secs) and particulate sorting (20 secs) using the Smart Dentin Grinder (Photo A) device.

3. Decontamination using a cleanser, followed by rinsing in a saline solution.

The system comprises a motor unit onto which the sterile, single-use grinding chamber is attached. These chambers grind the teeth that have been cleaned and sort the particulate by size. The granulate for the graft (250 to 1200 μ m in diameter) is collected in the top compartment of the unit on the left of the chamber and then placed in a sterile cup





tooth that has not undergone endodontic treatment. The bone loss is mainly associated with periodontal problems. Significant non-structural interference on the inn
and 27. | **Fig. 2:** Significant bone loss as regards the palatine root of 27. Pocket of approximately 9 mm in size highlighted by the periodontal probe. | **Fig. 3:** The peri
6 does not show any bone decay (3 mm). | **Fig. 4:** Palatine incision on the mesiolingual corner of 26 to the distolingual corner of 28. | **Fig. 5:** The tooth immediately a
ly free of all residues: desmodontal remainder of the periodontal and apical granuloma. | **Fig. 6:** The liberated tooth socket is carefully cleaned: all inflammatory tiss
ed from the radicular surface of the adjacent teeth and apical curettage is carried out. | **Fig. 7:** The tooth is cleaned using a tungsten carbide mill rather than a diamon
composite, glass ionomers) materials are removed as are all the infected and affected caries and all gingival, desmodontal and pathological tissue adhesions. | **Fig. 8:** Pl
sterile grinding chamber of the SMART DENTIN GRINDER. The first sifting allows all particulates smaller than 1200 !m to pass through. | **Fig. 9:** All the dentin and enam
passed through the first sieve by the end of the first grinding and sorting sequence (3 seconds and 20 seconds, respectively) . The particulates that are larger than
ing and sorting cycles so as to obtain as much graft material as possible. | **Fig. 10:** Only a few pulp-like elements remain in the grinding chamber after various crushin
cycles is preferred over a single, long crushing session, which is much less efficient. | **Fig. 11:** The particulate to be used for the bone graft (250 !m - 1200 !m in dia
the right on the photo). The particulate that have passed through the sieve (diameter less than 250 !m) cannot be used for the graft as their size | **Fig. 12:** The in